Journal of Invertebrate Pathology 139 (2016) 1–5

Contents lists available at ScienceDirect

Journal of Invertebrate Pathology

journal homepage: www.elsevier.com/locate/jip

Wound repair in *Pocillopora*

Jenny Carolina Rodríguez-Villalobos [a,*,1], Thierry Martin Work [b], Luis Eduardo Calderon-Aguilera [a]

[a] Departamento de Ecología Marina, Centro de Investigación Científica y de Educación Superior de Ensenada (CICESE), Carretera Ensenada-Tijuana, # 3918, Zona Playitas, C.P. 22860, Ensenada, BC, Mexico

[b] US Geological Survey, National Wildlife Health Center, Honolulu Field Station, 300 Ala Moana Blvd., Room 8-132, Honolulu, HI 96850, USA

ARTICLE INFO

Article history:
Received 17 January 2016
Revised 30 June 2016
Accepted 6 July 2016
Available online 7 July 2016

Keywords:
Healing
Tissue loss
Histopathology
Coral
Pocilloporidae
Pocillopora damicornis

ABSTRACT

Corals routinely lose tissue due to causes ranging from predation to disease. Tissue healing and regeneration are fundamental to the normal functioning of corals, yet we know little about this process. We described the microscopic morphology of wound repair in *Pocillopora damicornis*. Tissue was removed by airbrushing fragments from three healthy colonies, and these were monitored daily at the gross and microscopic level for 40 days. Grossly, corals healed by Day 30, but repigmentation was not evident at the end of the study (40 d). On histology, from Day 8 onwards, tissues at the lesion site were microscopically indistinguishable from adjacent normal tissues with evidence of zooxanthellae in gastrodermis. Inflammation was not evident. *P. damicornis* manifested a unique mode of regeneration involving projections of cell-covered mesoglea from the surface body wall that anastomosed to form gastrovascular canals.

© 2016 Elsevier Inc. All rights reserved.

1. Introduction

Invertebrates experience injuries from many sources, and tissue loss is one of the lesions more frequently seen in scleractinian corals (Lindsay, 2010; Moses and Hallock, 2015). In corals, tissue loss has many potential origins such as competition and predation (Rodriguez-Villalobos et al., 2015; Moses and Hallock, 2015), anchor-induced trauma, or infectious disease (Work et al., 2012). Many coral diseases such as White Syndrome, White Plague, White Band, and Skeletal Eroding Band, are characterized by tissue loss (Ainsworth et al., 2007; Page and Willis, 2008; Work and Aeby, 2011; Work et al., 2012), that in some cases present multiples aetiologies that could even change over time (Work et al., 2012).

Regardless of cause, corals have abilities to recover from injuries (Bak and Steward-Van Es, 1980; Kramarsky-Winter and Loya, 2000; Soong and Chen, 2003). Healing and regeneration play a vital role for the individual allowing recovery of tissue integrity that permits normal ecological and biological functions (Sonnemann and Bement, 2011; Giangrande and Licciano, 2014; da Silveira and van't Hof, 1977). However many factors, such as high nutrients concentration, sedimentation, turbidity, high irradiances (Moses and Hallock, 2015; Sabine et al., 2015), health condition of the individual (Ruiz-Diaz et al., 2016), coral species or morphology (Hall, 1997), and even size (Bak and Steward-Van Es, 1980) and morphology of lesion (Meesters et al., 1997) can influence the capacity of corals to recover from injuries thereby affecting reproduction, colony growth and defenses abilities against pathogens (Moses and Hallock, 2015).

Whilst there is considerable information on wound repair in corals at the gross level, studies of repair processes at the tissue and cell level are uncommon. Wound repair is a process that includes cell migration, adhesion, and contraction involving complex signaling pathways that begin immediately after injury (Brockes and Kumar, 2008). Wound repair, has been studied at the cellular level in some Cnidaria including soft corals (da Silveira and van't Hof, 1977; Meszaros and Bigger, 1999) anemones (Singer, 1971; Patterson and Landolt, 1979; Young, 1974), and recently the scleractinian corals *Montipora capitata* (Work and Aeby, 2010) and *Porites cylindrica* (Palmer et al., 2011). These studies show that regeneration of tissue in cnidaria occurs by different mechanisms. For instance, in the perforate coral *M. capitata*, wound repair does not involve migration of mesogleal cells to the site of injury region (Work and Aeby, 2010) in contrast to *Porites* (Palmer et al., 2011), soft corals (Meszaros and Bigger, 1999), and anemones (DuBuc et al., 2014) that all manifest a prominent inflammatory response. Calicoblastic or epidermal pluripotentiality in *Montipora* may play a role in tissue regeneration (Work and Aeby, 2010) whereas in *P. cylindrica*, wound repair is exemplified by formation of a clot or plug of degranulating melanin-containing

* Corresponding author.
E-mail address: jennica13@hotmail.com (J.C. Rodríguez-Villalobos).
[1] Current address: Universidad Autónoma de Baja California Sur, Departamento de Ciencias Marinas y Costeras, Carretera al Sur Km 5.5 Colonia el Mezquitito, La Paz, BCS, 23080, Mexico.

http://dx.doi.org/10.1016/j.jip.2016.07.002
0022-2011/© 2016 Elsevier Inc. All rights reserved.

cells and the aggregation of cell debris. In *Porites*, inflammation is evidenced by the aggregation of granular amoebocytes at the wound edge (Palmer et al., 2011).

While data exists on wound repair (at the cellular level) for two perforate scleractinian corals, we have no information on this process in non-perforate corals such as *Pocillopora* spp. Given the vast difference in tissue organization between these two groups, it is likely that the process of wound repair might differ. Understanding wound repair in *Pocillopora* is important, because this genus is dominant in the Mexican Pacific (Reyes-Bonilla, 2003) and is affected by unexplained tissue loss (White Syndrome) that is widespread (Rodríguez-Villalobos et al., 2014; Rodriguez-Villalobos et al., 2015). *Pocillopora* are also particular in the Mexican tropical Pacific in that they are the first to colonize high-energy sites where conditions are not optimal for growth (Calderón-Aguilera et al., 2007) suggesting that, in addition to rapid growth and recruitment (Coles and Brown, 2007), Pocilloporidae may have efficient tissue repair mechanisms in face of injuries. Understanding the morphologic markers of wound repair in this species might also inform interpretation of histopathology investigations, just as understanding of wound repair in *Montipora* has facilitated interpretation of microscopic lesions in this genus in the Central and Western Pacific (Work et al., 2015, 2014). Therefore, the aim of this study was to describe the gross and microscopic pathology of wound repair in *Pocillopora damicornis*.

2. Materials and methods

Three colonies of apparently healthy *P. damicornis* were collected from Pichilingue Bay, La Paz, BCS, Mexico and immediately transported to the laboratory. There, they were fragmented into ca. 3 cm pieces and placed into a single water tank (300 L) with flow through filtered (100 μm) seawater under ambient temperature and natural light. After fragmentation, a 1 cm wide section of tissue was removed at the base of the fragment using a double action airbrush (Paasche Air Brush®). All fragments (180 in total) were maintained in the same tank during the experiment. Tanks were cleaned by vacuuming the walls three to four times per week in order to prevent algal overgrowth. Two replicate fragments per colony were sampled following tissue removal on Day 0, and the process repeated daily until day 40. All fragments were photographed, fixed with 10% formalin seawater solution, and decalcified in HCl (10%) buffered with 0.7 g/L EDTA, 0.14 g/L sodium tartrate, 0.008 g/L potassium sodium tetrahydrate. Samples were then embedded in paraffin, sectioned (5 μm thick), and tissues were stained with Harris's hematoxylin and eosin (Humason, 1967). Two tissue sections (slides) per colony per day were analysed under microscope. For microscopic interpretation, tissues were divided into surface body wall (SBW) comprising the coenenchyme and polyp and the basal body wall (BBW) including mesenterial filaments. All experiments were done at the Laboratorio de Histología, Universidad Autónoma de Baja California Sur (UABCS).

3. Results

3.1. Gross pathology

At Day 0, the edge of the lesion appeared irregular with bare white skeleton bereft of tissues or small clumps of mucus. The lesion remained essentially unchanged until Day 8 when a smooth and white margin a few millimeters wide became evident progressing from the edge of pigmented tissues. This white tissue continued to overgrow bare skeleton at the base of the fragment as new polyps developed. Extended tentacles of the polyps were seen at day 30 onwards. Re-pigmentation of regenerating tissues was not evident during the 40 days of experimentation (Fig. 1).

3.2. Microscopic pathology

At Day 0, mesoglea of the BBW was exposed and bereft of cells and polyps (Fig. 2A and B). At day 2, bare mesoglea at the edge of the lesion began to be colonized by clusters of cuboidal cells mixed with mucocytes with formation of gastrovascular canals (Fig. 2C and D). Near the edge of the lesion, projections of mesoglea covered by cuboidal cells originated from SBW (Fig. 2C) and eventually

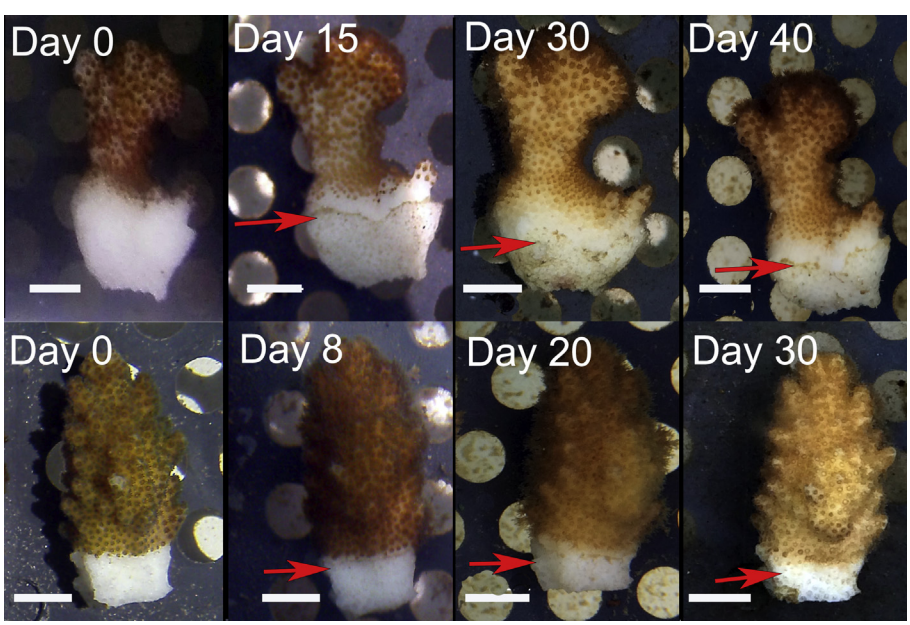

Fig. 1. Fragments of *Pocillopora* sp. with experimentally induced trauma showing progression of healing over time (red arrow). Scale bar = ca. 1 cm. Arrows at days 8–40 point to leading edge of apigmented regenerating tissues overgrowing bare skeleton. (For interpretation of the references to colour in this figure legend, the reader is referred to the web version of this article.)

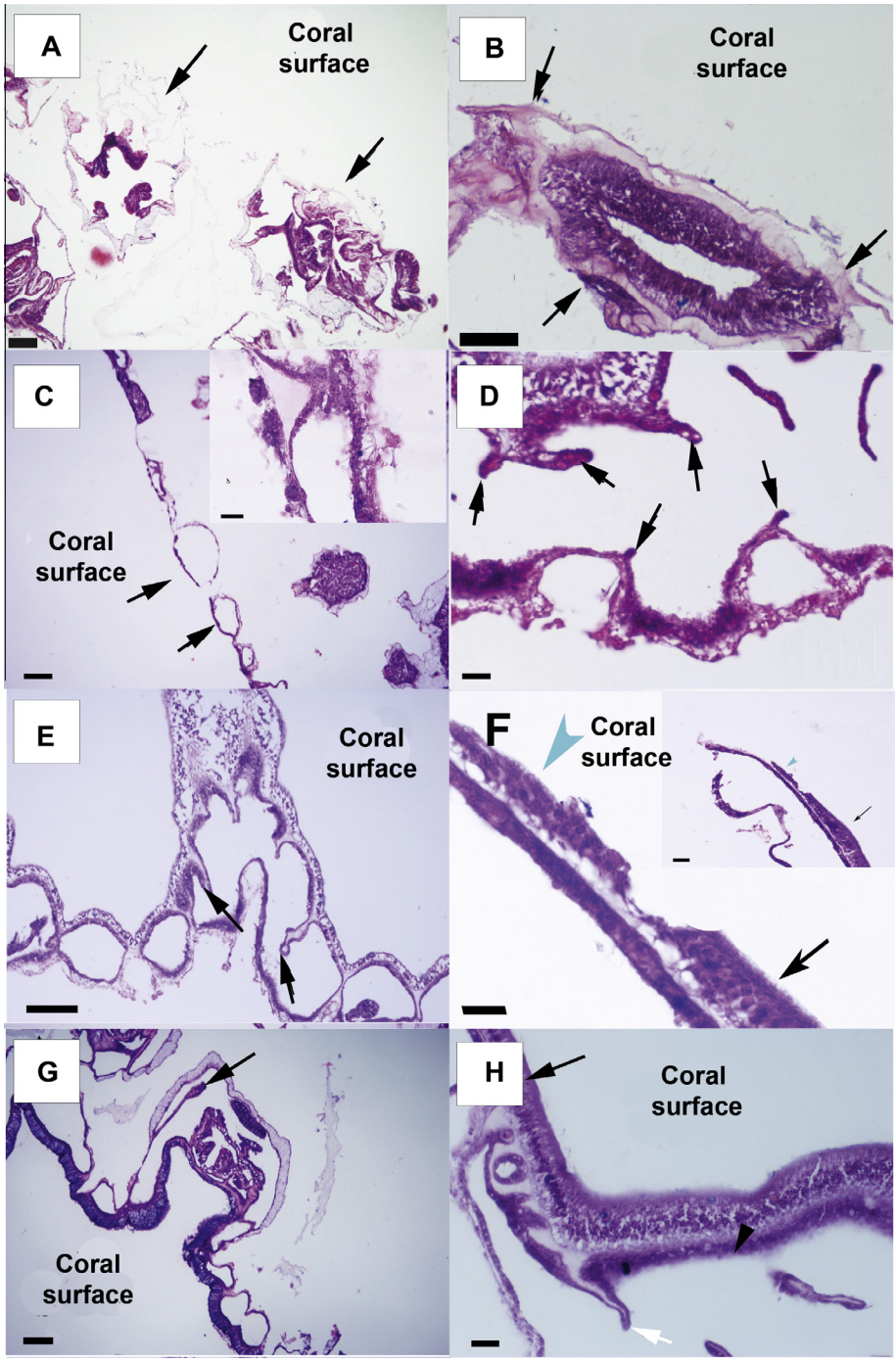

Fig. 2. Day 0. Wound edge. (A) Note bare mesoglea with lack of polyp structure (actinopharynx, tentacles) (arrows); bar = 100 μm. (B) Mesoglea (arrows) surrounding the remnant actinopharynx of a polyp in the edge of the wound; bar = 100 μm. Day 2. (C) Mostly acellular mesoglea (arrows); bar = 100 μm. Inset-close up of (C). Note projections of mesoglea covered by mixed cuboidal and mucus cells; bar = 10 μm. (D) *Primordial basal body wall*-Note buds of tissues comprising mesoglea colonized by sparse cuboidal cells protruding into gastrovascular canals (arrow); bar = 20 μm. Day 4. (E) Buds appear to elongate and anastomose forming basal body wall enclosing gastrovascular Canals (arrows); bar = 100 μm. (F) Epidermal regeneration. Note columnar cells (black arrow) interspersed with cuboidal cells (blue arrowhead); bar = 20 μm. Inset-lower magnification of same tissue with lesion edge on upper left; bar = 5 μm. Day 8. (G) Note formation of polyp and mesenterial filament (arrow) from coenenchyme; bar = 100 μm. (H) Surface body wall with complement of uniform columnar epidermal cells (black arrow) and cuboidal gastrodermis (arrowhead) with continued generation of basal body wall (white arrow) with characteristics expected for a healthy epithelia. Note also lack of zooxanthellaes; bar = 20 μm. (For interpretation of the references to colour in this figure legend, the reader is referred to the web version of this article.)

fused thus forming a *primordial basal body wall*. No zooxanthellae were observed in any tissue layer. By Day 4, primordial basal body walls projections anastomosed and formed gastrovascular canals (Fig. 2E). Within segmental areas of surface body wall, cuboidal epidermal cells transitioned to columnar morphology whilst mesoglea continued to be colonized by cuboidal cells (Fig. 2F).

From Day 8 onwards, polyp development was evident with formation of *mesenterial filaments* as extensions of mesoglea from calicodermis surrounded by cuboidal cells (Fig. 2G). Re-epithelialization was complete with normal characteristics of healthy columnar epidermis, mesoglea and gastrodermis (except by the absence of zooxanthellae) (Fig. 2H). By Day 40, tissues

at the lesion site were microscopically indistinguishable from adjacent normal tissues including the presence of zooxanthellae inside gastrodermal cells; however, grossly tissues remained white through the last day (40) of the experiment. Migration of mesogleal cells or other evidence of inflammatory infiltrates to the site of injury were not evident at any stage of the repair process. Gross and microscopic findings were essentially identical for fragments from all three colonies.

4. Discussion

Regeneration of tissue in *P. damicornis* had similarities and contrasts with wound repair in other cnidaria. From Day 2 until the end of the experiment, wound repair in *P. damicornis* was dominated by apparent migration of cells from the edge of the wound with no islands of regeneration and re-epithelialization as seen in *Montipora* (Work and Aeby, 2010). We suspect that this may in part be due to *Pocillopora* being a non-perforate coral that lacks a deep reservoir of tissue in the skeleton from where the tissue could be regenerated in contrast to perforate corals like *M. capitata* (Work and Aeby, 2010). This was illustrated by a unique aspect of wound repair in *P. damicornis* involving the formation of the BBW from buds of cell-covered mesoglea that anastomosed to form walls of gastrovascular canals, a phenomenon not seen in other scleractinia (Work and Aeby, 2010; Palmer et al., 2011). The relatively slow speed of repair in *Pocillopora* and *Montipora* contrasts with that of other cnidaria where this process occurs more rapidly. For instance, Hydra completely regenerates oral structures within 20 min of injury (Sparks, 1972), and within hours after damage in *Porites*, there was an increase in the amount of eosinophilic granular amoebocytes at the wound edge (Palmer et al., 2011).

There was no evidence of inflammation or migration of amoebocytes from mesoglea to the wound site in *P. damicornis*. The apparent absence of inflammatory cells seen in *P. damicornis* coincides with responses in some other cnidaria such as *Hydra* (Holstein et al., 2003) and *Montipora* (Work and Aeby, 2010) where inflammation is notably absent during wound repair. In this context, wound repair in those organisms is more akin to that of *Hydra* where tissue regeneration occurs by a process known as morphallaxis exemplified by reprogramming of existing cells without inflammation (Holstein et al., 2003). In contrast, other species of cnidaria mount a robust hypercellular response during wound repair. For instance, the repair process in *P. cylindrica* is characterized by phagocytosis and infiltrates of melanocytes (Palmer et al., 2011) whereas infiltrates of mesogleal cells are prominent at wound repair sites of soft corals (Meszaros and Bigger, 1999), anemones (Patterson and Landolt, 1979), and gorgonians (Olano and Bigger, 2000). Thus, patterns are becoming apparent where even within presumably simple organisms like Cnidaria, host response can vary dramatically, even within anatomically similar groups like the perforate corals *Porites* (Palmer et al., 2011) and *Montipora* (Work and Aeby, 2010). Exploring wound repair in other perforate *versus* non-perforate corals using histology and more advanced methodologies such as *in-situ* hybridization (DuBuc et al., 2014) might help confirm whether patterns seen here can be confirmed.

A final and cautionary aspect of this study is assuming that tissue loss is a progressive event in corals based on gross morphology alone (Work and Aeby, 2006). Clearly, in this study as in others (Work and Aeby, 2010), absent observation of animals over time, it is difficult to determine whether tissue loss is a degenerative or regenerative process. In this study, fragments with regenerating tissues looked superficially like white band diseases described in the literature (Bourne et al., 2015), yet close inspection revealed overgrowth of apigmented tissues over skeleton with cellular evidence of regeneration. Also, as in wound repair for *Montipora* (Work and Aeby, 2010), on histology, regenerated tissues in *P. damicornis* had what appeared to be a full complement of zooxanthellae in all compartments (basal and surface body wall) indistinguishable from adjacent normal tissues, yet tissues remained grossly apigmented. In addition to zooxanthellae, pigment proteins can play an important role in pigmentation of corals (Dove et al., 1995). Extending wound repair studies to include measurement of repigmentation and its mechanism might yield additional insights into this complex phenomenon.

Acknowledgments

This work was partially funded by SEMARNAT-INE-CONACYT (grant 23390 to LECA). JCRV was sponsored by CONACYT (CVU 339868). Authors especially thank to the Universidad Autónoma de Baja California Sur for allowing us the use of the facilities for the experiment. Dr. C. Rangel – Dávalos assisted us in the experimental design. C. Aguilar, J. Dominguez - Boza and C. Hernández - Carreón assisted in laboratory and fieldwork. Mention of products and trade names does not imply endorsement by the US Government.

References

Ainsworth, T., Kvennefors, E., Blackall, L., Fine, M., Hoegh-Guldberg, O., 2007. Disease and cell death in white syndrome of Acroporid corals on the Great Barrier Reef. Mar. Biol. 151, 19–29. http://dx.doi.org/10.1007/s00227-006-0449-3.

Bak, R.P.M., Steward-Van Es, Y., 1980. Regeneration of superficial damage in the Scleractinian Corals *Agaricia agaricites* f. Purpurea and *Porites astreoides*. Bull. Mar. Sci. 30, 883–887.

Bourne, D.G., Ainsworth, T.D., Pollock, F.J., Willis, B.L., 2015. Towards a better understanding of white syndromes and their causes on Indo-Pacific coral reefs. Coral Reefs 34, 233–242.

Brockes, J.P., Kumar, A., 2008. Comparative aspects of animal regeneration. Annu. Rev. Cell Dev. Biol. 24, 525–549. http://dx.doi.org/10.1146/annurev.cellbio.24.110707.175336.

Calderón-Aguilera, L.E., Reyes-Bonilla, H., Carriquiry, J.D., 2007. El papel de los arrecifes coralinos en el flujo de carbono en el océano: Estudios en el Pacífico Mexicano. In: CICESE (Ed.), El Carbono En Aguas Costeras Y Lacustres. SEMARNAT-CICESE, México, pp. 215–226.

Coles, S.L., Brown, E.K., 2007. Twenty-five years of change in coral coverage on a hurricane impacted reef in Hawaii: the importance of recruitment. Coral Reef 26, 705–717. http://dx.doi.org/10.1007/s00338-007-0257-3.

da Silveira, F.L., van't Hof, T., 1977. Regeneration in the gorgonian *Plexura flexuosa* (Cnidaria, Octocorallia). Bijdr. tot Dierkd. 47, 98–108.

Dove, S.G., Takabayashi, M., Hoegh-Guldberg, O., 1995. Isolation and partial characterization of the pink and blue pigments of pocilloporid and acroporid corals. Biol. Bull. 189, 288–297.

DuBuc, T.Q., Traylor-Knowles, N., Martindale, M.Q., 2014. Initiating a regenerative response, cellular and molecular features of wound healing in the nidarian *Nematostella vectensis*. BMC Biol. 12, 24.

Giangrande, A., Licciano, M., 2014. Regeneration and clonality in Metazoa. The price to pay for evolving complexity. Invertebr. Reprod. Dev. 58, 1–8.

Hall, V.R., 1997. Interspecific differences in the regeneration of artificial injuries on scleractinian corals. J. Exp. Mar. Biol. Ecol. 212, 9–23. http://dx.doi.org/10.1016/S0022-0981(96)02760-8.

Holstein, T.W., Hobmayer, E., Technau, U., 2003. Cnidarians: an evolutionarily conserved model system for regeneration? Dev. Dyn. 226, 257–267. http://dx.doi.org/10.1002/dvdy.10227.

Humason, G., 1967. Animal tissue techniques, second ed. W.H. Freeman and Company, United States of America.

Kramarsky-Winter, E., Loya, Y., 2000. Tissue regeneration in the coral *Fungia granulosa*: the effect of extrinsic and intrinsic factors. Mar. Biol. 137, 867–873. http://dx.doi.org/10.1007/s002270000416.

Lindsay, S.M., 2010. Frequency of injury and the ecology of regeneration in marine benthic invertebrates. Integr. Comp. Biol. 50, 479–493.

Meesters, E.H., Wesseling, I., Bak, R.P.M., 1997. Coral colony tissue damage in six species of reef-building corals: partial mortality in relation with depth and surface area. J. Sea Res. 37, 131–144. http://dx.doi.org/10.1016/S1385-1101(96)00004-4.

Meszaros, A., Bigger, C., 1999. Qualitative and quantitative study of wound healing processes in the coelenterate, Plexaurella fusifera: spatial, temporal, and environmental (light attenuation) influences. J. Invertebr. Pathol. 73, 321–331. http://dx.doi.org/10.1006/jipa.1999.4851.

Moses, E.F., Hallock, P., 2015. Coral regeneration assay. In: Diseases of Coral. John Wiley & Sons Inc., pp. 472–481. http://dx.doi.org/10.1002/9781118828502.ch35.

Olano, C.T., Bigger, C.H., 2000. Phagocytic activities of the gorgonian coral *Swiftia exserta*. J. Invertebr. Pathol. 76, 176–184. http://dx.doi.org/10.1006/jipa.2000.4974.

Page, C.A., Willis, B.L., 2008. Epidemiology of skeletal eroding band on the Great Barrier Reef and the role of injury in the initiation of this widespread coral disease. Coral Reefs 27, 257–272.

Palmer, C.V., Traylor-Knowles, N.G., Willis, B.L., Bythell, J.C., 2011. Corals use similar immune cells and wound-healing processes as those of higher organisms. PLoS ONE 6, e23992.

Patterson, M.J., Landolt, M.L., 1979. Cellular reaction to injury in the anthozoan *Anthopleura elegantissima*. J. Invertebr. Pathol. 33, 189–196. http://dx.doi.org/10.1016/0022-2011(79)90152-6.

Reyes-Bonilla, H., 2003. Coral reefs of the pacific coast of Mexico. In: Cortés, J. (Ed.), Latin American Coral Reefs. Elsevier Science B.V, Amsterdam, p. 479.

Rodríguez-Villalobos, J.C., Rocha-Olivares, A., Work, T.M., Calderon-Aguilera, L.E., Cáceres-Martínez, J.A., 2014. Gross and microscopic pathology of lesions in *Pocillopora* spp. from the subtropical eastern Pacific. J. Invertebr. Pathol. 120, 9–17.

Rodriguez-Villalobos, J.C., Work, T.M., Calderon-Aguilera, L.E., Reyes-Bonilla, H., Hernández, L., 2015. Explained and unexplained tissue loss in corals from the Tropical Eastern Pacific. Dis. Aquat. Organ. 116, 121–131.

Ruiz-Diaz, C.P., Toledo-Hernandez, C., Mercado-Molina, A.E., Pérez, M.-E., Sabat, A. M., 2016. The role of coral colony health state in the recovery of lesions. PeerJ 4, e1531.

Sabine, A.M., Smith, T.B., Williams, D.E., Brandt, M.E., 2015. Environmental conditions influence tissue regeneration rates in scleractinian corals. Mar. Pollut. Bull. 95, 253–264.

Singer, I.I., 1971. Tentacular and oral-disc regeneration in the sea anemone, *Aiptasia diaphana* III. Autoradiographic analysis of patterns of tritiated thymidine uptake. J. Embryol. Exp. Morphol. 26, 253–270.

Sonnemann, K.J., Bement, W.M., 2011. Wound repair: toward understanding and integration of single-cell and multicellular wound responses. Annu. Rev. Cell Dev. Biol. 27, 237–263.

Soong, K., Chen, T., 2003. Coral transplantation: regeneration and growth of *Acropora* fragments in a nursery. Restor. Ecol. 11, 62–71. http://dx.doi.org/10.1046/j.1526-100X.2003.00100.x.

Sparks, A.K., 1972. Reaction to injury and wound repair in invertebrates. In: Sparks, A.K. (Ed.), Invertebrate Pathology Noncommunicable Diseases. Academic Press, pp. 20–133. http://dx.doi.org/10.1016/B978-0-12-656450-1.50007-5.

Work, T.M., Aeby, G.S., 2011. Pathology of tissue loss (white syndrome) in *Acropora* sp. corals from the Central Pacific. J. Invertebr. Pathol. 107, 127–131.

Work, T.M., Aeby, G.S., 2010. Wound repair in *Montipora capitata*. J. Invertebr. Pathol. 105, 116–119.

Work, T.M., Aeby, G.S., 2006. Systematically describing gross lesions in corals. Dis. Aquat. Organ. 70, 155–160.

Work, T.M., Aeby, G.S., Hughen, K.A., 2015. Gross and microscopic lesions in corals from Micronesia. Vet. Pathol. 53, 153–162.

Work, T.M., Aeby, G.S., Lasne, G., Tribollet, A., 2014. Gross and microscopic pathology of hard and soft corals in New Caledonia. J. Invertebr. Pathol. 120, 50–58. http://dx.doi.org/10.1016/j.jip.2014.05.007.

Work, T.M., Russell, R., Aeby, G.S., 2012. Tissue loss (white syndrome) in the coral *Montipora capitata* is a dynamic disease with multiple host responses and potential causes. Proc. R. Soc. B Biol. Sci. 279, 4334–4341. http://dx.doi.org/10.1098/rspb.2012.1827.

Young, J.A.C., 1974. The nature of tissue regeneration after wounding in the sea anemone *Calliactis parasitica* (Couch). J. Mar. Biol. Assoc. United Kingdom 54, 599–617.